



# Clinical Thyroidology<sup>®</sup> for the Public

VOLUME 11 | ISSUE 10 | OCTOBER 2018

**EDITOR'S COMMENTS .....2****THYROID FUNCTION IN PREGNANCY.....3****Association of thyroid function in mothers during early pregnancy with the risk of autism spectrum disorder and attention-deficit/hyperactivity disorder in children**

Thyroid dysfunction in mothers during pregnancy can have adverse effect on the baby's brain development. Recently, there has been interest in looking at the effects of abnormal thyroid hormone levels in mothers on other outcomes of babies' brain development, such as ADHD and autism. This study aimed to investigate potential associations between thyroid abnormalities in mothers during pregnancy and diagnoses of ADHD and autism.

Andersen SL et al 2018 Maternal thyroid function in early pregnancy and child neurodevelopmental disorders: a Danish nationwide case-cohort study. *Thyroid* 28:537–546. Epub 2018 Mar 27. PMID: 29584590.

**THYROID NODULE .....5****Can the rate of thyroid nodules that are non-diagnostic after a biopsy be reduced?**

Non-diagnostic thyroid biopsies can occur in up to 10% of biopsies and usually require a repeat biopsy. There are two separate techniques of doing the thyroid biopsies: the aspiration technique and the capillary action technique. This study reviewed 24 published studies to compare the rate of non-diagnostic biopsy between these 2 techniques.

Moss WJ et al 2018 Needle biopsy of routine thyroid nodules should be performed using a capillary action technique with 24- to 27-gauge needles: a systematic review and meta-analysis. *Thyroid* 28:857–863. Epub 2018 Jun 5. PMID: 29742978.

**THYROID CANCER.....7****Small bright spots with comet-tails noted on ultrasound may be indicative of cancer when occurring in the solid portion of a thyroid nodule**

Several thyroid nodule features noted on ultrasound are suggestive of thyroid cancer. While small bright spots known as microcalcifications usually indicate a cancer, small bright spots with a comet tail are usually associated with a benign thyroid nodule. The goal of this study was to evaluate the frequency and types of small bright spots present in cancerous and non-cancerous thyroid nodules.

Wu H et al 2018 Echogenic foci with comet-tail artifact in resected thyroid nodules: not an absolute predictor of benign disease. *PLoS One* 13:e0191505. PMID: 29352286.

**THYROID NODULES .....9****The American Thyroid Association ultrasound classification system can help determine the risk of cancer in indeterminate thyroid nodules**

The ATA guidelines for management of thyroid nodule offers a system for classifying thyroid nodules as to concern for thyroid cancer depending on the findings of ultrasound. The current study evaluated the ability of the ATA guidelines classification system to predict cancer in nodules with indeterminate biopsies.

Valderrabano P et al Thyroid Nodules with Indeterminate Cytology: Utility of the American Thyroid Association Sonographic Patterns for Cancer Risk Stratification. *Thyroid* (2018) 28: 1004–1012 (PMID: 29848195)

**THYROID NODULES .....11****How accurate is an updated molecular test in diagnosing cancer in indeterminate thyroid biopsies?**

Indeterminate biopsy results can occur in 15–20% of biopsies. There has been great interest in developing molecular tests to determine whether nodules with indeterminate biopsy are cancerous or not. In this study, the authors report on the diagnostic accuracy of an updated molecular test in diagnosing cancer in indeterminate thyroid biopsies.

Patel KN et al 2018 Performance of a genomic sequencing classifier for the preoperative diagnosis of cytologically indeterminate thyroid nodules. *JAMA Surg*. Epub 2018 May 23.

**THYROID CANCER.....13****Extent of initial surgery may not significantly change survival in patients with localized medullary thyroid cancer**

The recommended initial operation for patients with medullary thyroid cancer includes thyroidectomy and removal of the lymph nodes in the central neck. Current guidelines differ on how best to approach a patient with less than the recommended initial operation. The goal of this study was to evaluate the survival of patients with medullary thyroid cancer with localized cancer based on the extent of the initial operation.

Randle RW et al 2018 Survival in patients with medullary thyroid cancer after less than the recommended initial operation. *J Surg Oncol* 117:1211–1216. Epub 2017 Dec 19. PMID: 29266278.

**ATA ALLIANCE FOR THYROID PATIENT EDUCATION .....15****2018 ATA Alliance for Thyroid Patient****Education Health Forum.....16****ATA Brochure: Thyroid Nodules.....19**



**www.thyroid.org**

**Editor**

Alan P. Farwell, MD, FACE  
Boston Medical Center  
Boston University School of Medicine  
720 Harrison Ave., Boston, MA 02115  
American Thyroid Association  
Email: [thyroid@thyroid.org](mailto:thyroid@thyroid.org)  
[www.thyroid.org/patients/ct/index.html](http://www.thyroid.org/patients/ct/index.html)

**Editorial Board**

Jessie Block-Galaraza, MD, Albany, NY  
Gary Bloom, New York, NY  
Alina Gavrilă, MD, MMSC, Boston, MA  
Melanie Goldfarb, MD, MS, FACS, FACE,  
Santa Monica, CA  
Shirin Haddady, MD, MPH, Boston, MA  
Sun Lee, MD, Boston, MA  
Angela Leung, MD, Los Angeles, CA  
Priya Mahajan, MD, Houston, TX  
Maria Papaleontiou, MD, Ann Arbor, MI  
Anna M. Sawka, MD, Toronto, ON, Canada  
Phillip Segal, MD, Toronto, ON, Canada  
Vibhatsu Sharma, MD, Albany, NY  
Valentina Tarasova, MD, Tampa, FL  
Whitney Woodmansee, MD, Gainesville, FL

**American Thyroid Association**

**President**

Charles H. Emerson, MD (2017–2018)

**Secretary/Chief Operating Officer**

Victor J. Bernet, MD (2015–2019)

**Treasurer**

Julie Ann Sosa, MD (2017–2021)

**President-Elect**

Elizabeth N. Pearce, MD, MSc (2017–2018)

**Past-President**

John C. Morris, MD (2017–2018)

**Executive Director**

Barbara R. Smith, CAE  
American Thyroid Association  
6066 Leesburg Pike, Suite 550  
Falls Church, VA 22041  
Telephone: 703-998-8890  
Fax: 703-998-8893  
Email: [thyroid@thyroid.org](mailto:thyroid@thyroid.org)

**Designed by**

Karen Durland, [kdurland@gmail.com](mailto:kdurland@gmail.com)

**Clinical Thyroidology for the Public**

Copyright © 2018 by the American Thyroid Association, Inc. All rights reserved.



## EDITOR'S COMMENTS

Welcome to another issue of *Clinical Thyroidology for the Public*. In this journal, we will bring to you the most up-to-date, cutting edge thyroid research. We also provide even faster updates of late-breaking thyroid news through [Twitter](#) at [@thyroidfriends](#) and on [Facebook](#). Our goal is to provide patients with the tools to be the most informed thyroid patient in the waiting room. Also check out our friends in the **Alliance for Thyroid Patient Education**. The **Alliance** member groups consist of: the *American Thyroid Association*, *Bite Me Cancer*, the *Graves' Disease and Thyroid Foundation*, the *Light of Life Foundation*, *ThyCa: Thyroid Cancer Survivors' Association*, *Thyroid Cancer Canada*, *Thyroid Cancer Alliance* and *Thyroid Federation International*.

We invite all of you to join our **Friends of the ATA** community. It is for you that the American Thyroid Association (ATA) is dedicated to carrying out our mission of providing reliable thyroid information and resources, clinical practice guidelines for thyroid detection and treatments, resources for connecting you with other patients affected by thyroid conditions, and cutting edge thyroid research as we search for better diagnoses and treatment outcomes for thyroid disease and thyroid cancer. We thank all of the Friends of the ATA who support our mission and work throughout the year to support us. We invite you to help keep the ATA mission strong by choosing to make a donation that suits you – it takes just one moment to give online at: [www.thyroid.org/donate](http://www.thyroid.org/donate) and all donations are put to good work. The ATA is a 501(c)3 nonprofit organization and your gift is tax deductible.

October is **[Thyroid Nodule Awareness Month](#)**.

If you are in Washington, DC, please join us for a free Patient Forum on Saturday, October 6 at the Marriot Marquis from 2–4 PM.

In this issue, the studies ask the following questions:

- Is there an association between thyroid dysfunction in the mother and the development of autism and ADHD in the children?
- Does the type of nodule biopsy technique affect the frequency of non-diagnostic samples?
- Are small bright spots noted on ultrasound associated with thyroid cancer?
- Can the ATA ultrasound classification system help determine the risk of cancer in indeterminate thyroid nodules?
- Can a new version of a molecular marker assay improve the diagnosis of cancer in indeterminate thyroid nodules?
- Is survival the best endpoint in determining the extent of surgery in medullary thyroid cancer?

We welcome your feedback and suggestions. Let us know what you want to see in this publication. I hope you find these summaries interesting and informative.

— Alan P. Farwell, MD, FACE



## THYROID FUNCTION IN PREGNANCY

### Association of thyroid function in mothers during early pregnancy with the risk of autism spectrum disorder and attention-deficit/hyperactivity disorder in children

#### BACKGROUND

Adequate thyroid hormone in pregnancy is important for normal brain development in babies. During the critical stages of brain development in early pregnancy, a baby depends on thyroid hormone being delivered from mother through placenta, as a baby is not able to make his/her own thyroid hormone until much later in pregnancy.

We know that severe (overt) hypothyroidism in mothers during pregnancy can have adverse effect on the baby's development, such as lower IQ scores. However, effects of mild (subclinical) hypothyroidism or mild (subclinical) hyperthyroidism in mother during pregnancy are less clear. There has also been interest in looking at the effects of abnormal thyroid hormone levels in mothers on other outcomes of babies' brain development, such as attention-deficit/hyperactivity disorder (ADHD) and autism spectrum disorder (ASD).

This study aimed to investigate potential associations between thyroid abnormalities in mothers during pregnancy and diagnoses of ADHD and ASD in children.

#### THE FULL ARTICLE TITLE

Andersen SL et al 2018 Maternal thyroid function in early pregnancy and child neurodevelopmental disorders: a Danish nationwide case-cohort study. *Thyroid* 28:537–546. Epub 2018 Mar 27. PMID: 29584590.

#### SUMMARY OF THE STUDY

A total of 7,624 mother-child pairs were selected randomly from Danish Nationwide Birth Cohort in Denmark, which included pregnant women from 1997 and 2003. All of the mothers in the study had blood drawn in early pregnancy (between 5–19 weeks) and had thyroid hormone (TSH and free T<sub>4</sub>) levels measured. A total of 2,276 children in the study had diagnoses of brain development disorders that have been identified by looking at medical records, including febrile seizure (n

= 489), epilepsy (n = 375), developmental disorder (n = 174), ASD (n = 302), or ADHD (n = 1143). A total of 5,348 children without diagnoses of brain disorders were used to compare with those with diagnoses. The study assessed potential association between hypothyroidism, hyperthyroidism, and low free T<sub>4</sub> levels in mothers and diagnoses of brain development disorders in children.

Both subclinical hypothyroidism and overt hyperthyroidism in the mothers were associated with increased risk of ASD in children (70% and 118%, respectively). Interestingly, subclinical hyperthyroidism in the mothers was associated with a 65% decreased risk of ASD in children. Low thyroid hormone levels in the mothers showed a trend towards increased risk of ASD in children, but was associated with a 46% increased risk of ADHD in children. These associations were present in both boys and girls. Overt hyperthyroidism in the mothers was also associated with a 188% increased risk of epilepsy diagnosed before 1 year of age in children, but not later in life.

There were no associations between thyroid dysfunction in the mother and febrile seizures, epilepsy, or other developmental disorders in children.

#### WHAT ARE THE IMPLICATIONS OF THIS STUDY?

Both subclinical hypothyroidism and overt hyperthyroidism in mothers in pregnancy were associated with increased risk of autism spectrum disorders in children. Low thyroid hormone level in mothers was associated with increased risk of ADHD in children. Because the frequency of ASD and ADHD is generally low and thyroid hormone levels are not routinely checked in pregnant women, it is difficult to study the potential relationship between thyroid dysfunction in the mother and these diagnoses in children. The advantage of this study was large number of study participants with thyroid hormone levels available during early pregnancy.





## THYROID FUNCTION IN PREGNANCY, continued

The cause of ASD and ADHD are thought to be from combination of many different factors. Therefore, it is difficult to say whether abnormal thyroid hormone levels in mothers in pregnancy is the main cause of development of ASD or ADHD in children or simply plays a role. Further, there is no evidence that treatment of the thyroid disorders in mothers would have any effect on the findings of this study. However, given the findings

of this study showing association between both low and high thyroid function in mothers in pregnancy with ASD in children, and between low thyroid function in mothers in pregnancy with ADHD in children, pregnant women with thyroid disease should be carefully monitored to ensure adequate treatment and to avoid overtreatment of thyroid disease.

— Sun Lee, MD

### ATA THYROID BROCHURE LINKS

Pregnancy and Thyroid Disease: <https://www.thyroid.org/thyroid-disease-pregnancy/>

Thyroid Function Tests: <https://www.thyroid.org/thyroid-function-tests/>

### ABBREVIATIONS & DEFINITIONS

**TSH: thyroid stimulating hormone** — produced by the pituitary gland that regulates thyroid function; also the best screening test to determine if the thyroid is functioning normally.

**Thyroxine (T<sub>4</sub>):** the major hormone produced by the thyroid gland. T<sub>4</sub> gets converted to the active hormone T<sub>3</sub> in various tissues in the body.

**Hyperthyroidism:** a condition where the thyroid gland is overactive and produces too much thyroid hormone. Hyperthyroidism may be treated with antithyroid meds (Methimazole, Propylthiouracil), radioactive iodine or surgery.

**Overt Hyperthyroidism:** clear hyperthyroidism with a decreased TSH and an increased T<sub>4</sub> level.

**Subclinical Hyperthyroidism:** a mild form of hyperthyroidism where the only abnormal hormone level is a decreased TSH.

**Hypothyroidism:** a condition where the thyroid gland is underactive and doesn't produce enough thyroid hormone. Treatment requires taking thyroid hormone pills.

**Overt Hypothyroidism:** clear hypothyroidism with an increased TSH and a decreased T<sub>4</sub> level. All patients with overt hypothyroidism are usually treated with thyroid hormone pills.

**Subclinical Hypothyroidism:** a mild form of hypothyroidism where the only abnormal hormone level is an increased TSH. There is controversy as to whether this should be treated or not.







## THYROID NODULE

### Can the rate of thyroid nodules that are non-diagnostic after a biopsy be reduced?

#### BACKGROUND

Thyroid nodules are very common, occurring in up to 50% of patients. The concern about a thyroid nodule is whether this represents a thyroid cancer, which occurs in 5–6% of thyroid nodules. Depending upon the size and appearance of the nodule on ultrasound, the next step to evaluate a nodule is a thyroid biopsy. In general, there are two separate techniques of doing the procedure. Both require placement of a needle into the nodule but the method of collecting the sample differs. In the aspiration technique the sample is obtained by suction into a syringe whereas in the non-aspiration technique the sample is collected in a needle (called capillary action).

In up to 10% of biopsies, a diagnosis cannot be made since there are too few cells and the result is called non-diagnostic. In some cases, such as aspiration of a cyst where few cells would be present, this is expected. In other nodules, a non-diagnostic results usually requires a repeat biopsy. This study reviewed 24 published studies to compare the rate of non-diagnostic biopsy between the aspiration technique and the capillary action technique.

#### THE FULL ARTICLE TITLE

Moss WJ et al 2018 Needle biopsy of routine thyroid nodules should be performed using a capillary action

technique with 24- to 27-gauge needles: a systematic review and meta-analysis. *Thyroid* 28:857–863. Epub 2018 Jun 5. PMID: 29742978.

#### SUMMARY OF THE STUDY

This study reviewed 24 studies, with a total of 4428 thyroid nodules; 20 of these compared biopsies using capillary action and aspiration, while 6 evaluated the size of the needles. The results of the study indicate that the rate of non-diagnostic samples were significantly lower in patients undergoing biopsy through capillary action as opposed to suction /aspiration. Smaller needles were also better as compared to larger gauge needles.

#### WHAT ARE THE IMPLICATIONS OF THIS STUDY?

This study suggests that biopsies done by capillary action rather than on aspiration leads to a significant reduction in the rate of non-diagnostic results. This is important for patients, as per current practice guidelines most of these nodules would require a repeat biopsy. This often leads to a delay in diagnosis and contributes to a patient's concerns and anxiety.

—Vibhavasu Sharma, MD, FACE

#### ATA THYROID BROCHURE LINKS

Fine Needle Aspiration Biopsy of Thyroid Nodules: <https://www.thyroid.org/fna-thyroid-nodules/>

Thyroid Nodules: <https://www.thyroid.org/thyroid-nodules/>





## THYROID NODULE, continued

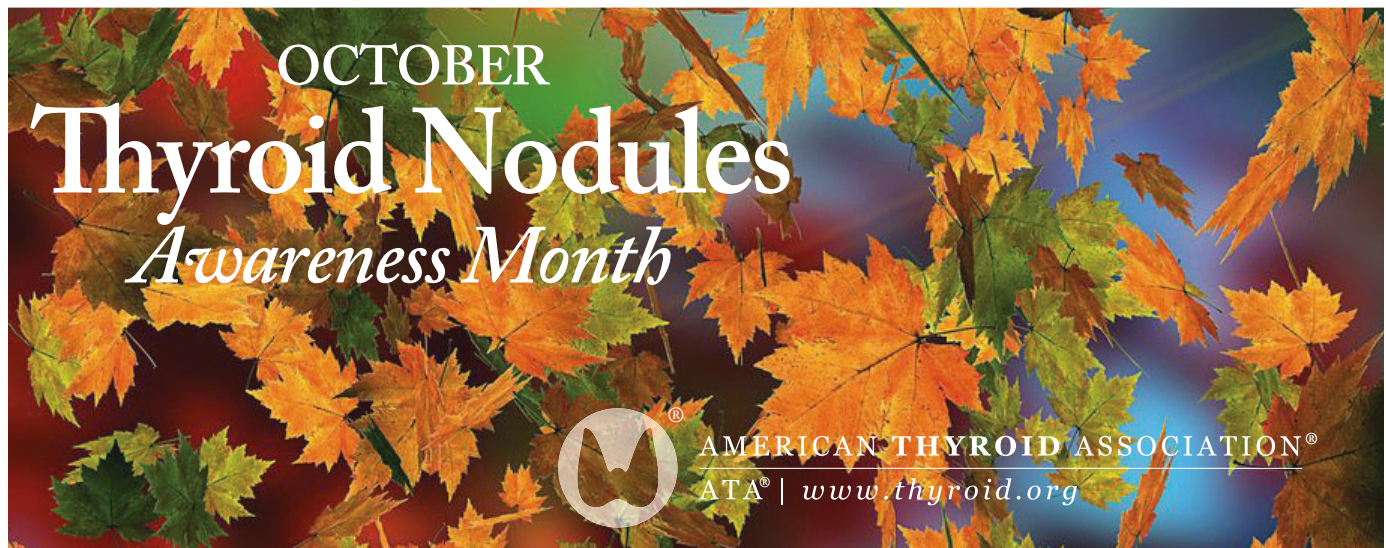
### ABBREVIATIONS & DEFINITIONS

**Thyroid nodule:** an abnormal growth of thyroid cells that forms a lump within the thyroid. While most thyroid nodules are non-cancerous (Benign), ~5% are cancerous.

**Thyroid fine needle aspiration biopsy (FNAB):** a simple procedure that is done in the doctor's office to determine if a thyroid nodule is benign (non-cancerous) or cancer. The doctor uses a very thin needle to withdraw cells from the thyroid nodule. Patients usually return home or to work after the biopsy without any ill effects.

**Inadequate/Insufficient biopsy:** this happens with not enough cells are obtained during the biopsy to provide a diagnosis. This occurs in 5–10% of biopsies. This often results in the need to repeat the biopsy.

**Non-diagnostic thyroid biopsy:** this happens when some atypical cells are found but not enough to provide a diagnosis. This occurs in 5–10% of biopsies. This often results in the need to repeat the biopsy.





## THYROID CANCER

### Small bright spots with comet-tails noted on ultrasound may be indicative of cancer when occurring in the solid portion of a thyroid nodule

#### BACKGROUND

The best imaging method for evaluation of thyroid nodules is ultrasound. According to the American Thyroid Association guidelines, all patients with thyroid nodules should undergo ultrasound evaluation to evaluate their cancer risk and decide whether a thyroid biopsy is indicated. Several thyroid nodule features noted on ultrasound are suggestive of thyroid cancer. For example, up to 95% of thyroid nodules with small bright spots known as microcalcifications are cancerous. However, not all small bright spots noted on ultrasound represent microcalcifications. In particular, small bright spots with a feature known as a comet tail are usually associated with a benign thyroid nodule. However, the significance of the small bright spots with comet-tail is not completely evaluated. The goal of this study was to evaluate the frequency and types of bright spots with comet-tail present in cancerous and non-cancerous thyroid nodules removed surgically.

#### THE FULL ARTICLE TITLE

Wu H et al 2018 Echogenic foci with comet-tail artifact in resected thyroid nodules: not an absolute predictor of benign disease. PLoS One 13:e0191505. PMID: 29352286.

#### SUMMARY OF THE STUDY

The study included 556 patients who underwent thyroid surgery at a single institution in China between January and September 2016, and had complete data available. Indications for thyroid surgery included abnormal results on ultrasound-guided thyroid biopsy, ultrasound findings suspicious for cancer, or local pressure symptoms clinically.

All patients underwent routine thyroid ultrasound prior to the surgery. A total of 962 thyroid nodules were identified in the 556 study patients. Among these, 71 thyroid nodules were noted to have bright spots with comet-tail with 46 of these nodules being cancerous and 25 being

benign. Most cancerous nodules represented papillary thyroid cancer, with one follicular thyroid cancer and one medullary thyroid cancer noted.

The bright spots with comet-tail noted on ultrasound were divided into three groups: type 1, located in the cystic portion of a thyroid nodule; type 2, intermediate type, located at the margin of a solid portion with the comet-tail in the cystic portion of a nodule or vice versa; and type 3, both the bright spot and comet-tail located in the solid portion of the nodule. If the thyroid nodules showed more than one type of bright spots, the predominant type was recorded. The shape of the comet-tail was classified into two types: a typical appearance of a reverse triangle or a fine linear bright area.

None of the cancerous thyroid nodules had the type I bright spots with comet-tail located in the cystic portion of a nodule. Bright spots with comet-tail associated with a solid portion of a nodule (types 2 and 3) were present in all cancerous nodules, and in most (18 of 25) non-cancerous thyroid nodules. There was no significant difference between cancerous and non-cancerous thyroid nodules regarding the shape of the bright spots with a classic triangular or a linear comet-tail.

#### WHAT ARE THE IMPLICATIONS OF THIS STUDY?

Small bright spots with comet-tail noted on ultrasound may predict a non-cancerous thyroid nodule when located freely in the cystic portion of the nodule, however, they may be associated with thyroid cancer when located in the solid portion of the nodule. These findings support the recommendation to use a combination rather than isolated features noted on ultrasound to evaluate the cancer risk of thyroid nodules.

—Alina Gavrilă, MD, MMSC





## THYROID CANCER, continued

### ATA THYROID BROCHURE LINKS

Thyroid Nodules: <https://www.thyroid.org/thyroid-nodules/>

Papillary and Follicular Thyroid Cancer: <https://www.thyroid.org/thyroid-cancer/>

### ABBREVIATIONS & DEFINITIONS

**Thyroid nodule:** an abnormal growth of thyroid cells that forms a lump within the thyroid. While most thyroid nodules are non-cancerous (benign), ~5–10% are cancerous (malignant).

**Thyroid ultrasound:** a common imaging test used to evaluate the structure of the thyroid gland. Ultrasound uses soundwaves to create a picture of the structure of the thyroid gland and accurately identify and characterize nodules within the thyroid. Ultrasound is also frequently used to guide the needle into a nodule during a thyroid nodule biopsy.

**Microcalcifications:** Small flecks of calcium within a thyroid nodule, usually seen as small bright spots on ultrasonography. These are frequently seen in nodules containing papillary thyroid cancer.

**Thyroid biopsy:** a simple procedure that is done in the doctor's office to determine if a thyroid nodule is

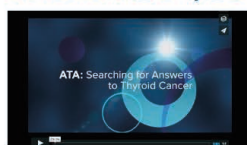benign (non-cancerous) or cancer. The doctor uses a very thin needle to withdraw cells from the thyroid nodule. Patients usually return home or to work after the biopsy without any ill effects.

**Papillary thyroid cancer:** the most common type of thyroid cancer. There are 4 variants of papillary thyroid cancer: classic, follicular, tall-cell and noninvasive follicular thyroid neoplasm with papillary-like nuclear features (NIFTP).

**Follicular thyroid cancer:** the second most common type of thyroid cancer.

**Medullary thyroid cancer:** a relatively rare type of thyroid cancer that often runs in families. Medullary cancer arises from the C-cells in the thyroid.

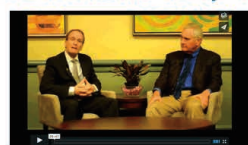### Watch how your donations help find answers to thyroid cancer



The American Thyroid Association (ATA) – Searching for Answers to Thyroid Cancer  
April 17, 2016



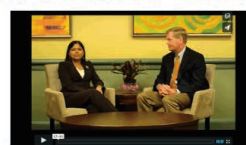13



Differentiated Thyroid Cancer – Support ATA's ongoing Research  
April 17, 2016



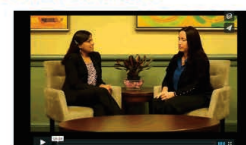19



Medullary Thyroid Cancer – Help the ATA Find a Cure  
April 17, 2016



10



Anaplastic Thyroid Cancer – Support Research for Treatments  
April 17, 2016



11

[www.thyroid.org/donate/](http://www.thyroid.org/donate/)







## THYROID NODULES

### The American Thyroid Association ultrasound classification system can help determine the risk of cancer in indeterminate thyroid nodules

#### BACKGROUND

Thyroid nodules are very common, occurring in up to 50% of patients. The best imaging method for evaluation of thyroid nodules is ultrasound. The American Thyroid Association guidelines for management of thyroid nodule offers a system for classifying thyroid nodules from benign to very low, low, intermediate and highly suspicious for thyroid cancer depending on the findings of ultrasound. This helps clinicians to choose the right thyroid nodule for thyroid biopsy.

Up to 20% of thyroid nodule biopsies come back as indeterminate, meaning a diagnosis of cancer or benign cannot be made looking at the cells alone. The chance of thyroid cancer in these nodules ranges from 5 to 30%. For further evaluation, a repeat biopsy using molecular markers to determine the risk of cancer can be helpful. Alternatively, surgery can be used to establish a definitive diagnosis. The current study evaluated the ability of The American Thyroid Association guidelines classification system to predict cancer in nodules with indeterminate biopsies.

#### THE FULL ARTICLE TITLE

Valderrabano P et al Thyroid Nodules with Indeterminate Cytology: Utility of the American Thyroid Association Sonographic Patterns for Cancer Risk Stratification. *Thyroid* (2018) 28: 1004-1012 (PMID: 29848195)

#### SUMMARY OF THE STUDY

The study was conducted by researchers in H Lee Moffit Cancer Center and Research Institute in Tampa, Florida. A total of 3325 thyroid biopsies done in this center from 2008 to 2015, with 861 ended up with indeterminate results. The final diagnosis (benign or cancer) was available for 463 of these nodules after surgery.

Three different physicians (one endocrinologist and two radiologists) reviewed the ultrasound images of these 463 nodules with indeterminate biopsy results. They classified these nodules independently according to The American Thyroid Association guidelines classification system to very low, low, intermediate and highly suspicious for thyroid cancer. A total of 5% of nodules were characterized as very low, 34% as low, 16% as intermediate and 8% as highly suspicious for thyroid cancer. Due to disagreement of the three physicians, 37% of the nodules were not assigned into any groups.

No cancer was found in nodules found in the very low category. A total of 20% of nodules ranked in the low or intermediate category were found to be cancerous. In nodules found to be in high-suspicious risk group, 56% were cancer. Of the nodules which were not assigned into any of the groups, 36% of were found to be cancerous after surgery.

Thyroid cancer with aggressive features like spread outside of the thyroid were predominantly in the highly suspicious group based on ultrasound.

#### WHAT ARE THE IMPLICATIONS OF THIS STUDY?

The authors concluded that The American Thyroid Association guidelines classification system could help to predict the chance of thyroid cancer in indeterminate nodules. Nodules identified highly suspicious by ultrasound have a higher chance of thyroid cancer.

— Shirin Haddady, MD

#### ATA THYROID BROCHURE LINKS

Papillary and Follicular Thyroid Cancer: <https://www.thyroid.org/thyroid-cancer/>

Thyroid Nodules: <https://www.thyroid.org/thyroid-nodules/>





## THYROID NODULES, continued

### ABBREVIATIONS & DEFINITIONS

**Thyroid nodule:** an abnormal growth of thyroid cells that forms a lump within the thyroid. While most thyroid nodules are non-cancerous (Benign), ~5% are cancerous.

**Thyroid Ultrasound:** a common imaging test used to evaluate the structure of the thyroid gland. Ultrasound uses soundwaves to create a picture of the structure of the thyroid gland and accurately identify and characterize nodules within the thyroid. Ultrasound is also frequently used to guide the needle into a nodule during a thyroid nodule biopsy.

**Thyroid biopsy:** a simple procedure that is done in the doctor's office to determine if a thyroid nodule is benign (non-cancerous) or cancer. The doctor uses a very thin needle to withdraw cells from the thyroid nodule. Patients usually return home or to work after the biopsy without any ill effects.

**Indeterminate thyroid biopsy:** this happens usually when the diagnosis is a follicular or hurthle cell lesion. Follicular and hurthle cells are normal cells found in the thyroid. Current analysis of thyroid biopsy results cannot differentiate between follicular or hurthle cell cancer from noncancerous adenomas. This occurs in 15–20% of biopsies and often results in the need for surgery to remove the nodule.

**Molecular markers:** genes and microRNAs that are expressed in benign or cancerous cells. Molecular markers can be used in thyroid biopsy specimens to either to diagnose cancer or to determine that the nodule is benign.

[www.thyroid.org/donate/](http://www.thyroid.org/donate/)



Support Thyroid Research





## THYROID NODULES

### How accurate is an updated molecular test in diagnosing cancer in indeterminate thyroid biopsies?

#### BACKGROUND

Thyroid nodules are very common, occurring in up to 50% of patients. The concern about a thyroid nodule is whether this represents a thyroid cancer, which occurs in 5–6% of thyroid nodules. Depending upon the size and appearance of the nodule on ultrasound, the next step to evaluate a nodule is a thyroid biopsy. Indeterminate biopsy results can occur in 15–20% of biopsies. This happens when a few atypical cells are seen but not enough to be called cancer (atypia of unknown significance (AUS) or follicular lesion of unknown significance (FLUS)) or when the diagnosis is a follicular or hurthle cell lesion. The majority of indeterminate nodules are not cancerous (although cancer rates may vary among institutions). Yet more than 1/3rd of patients with indeterminate thyroid nodule biopsies undergo thyroid surgery to establish a definitive diagnosis and in about half of these cases, thyroid cancer is diagnosed.

There has been great interest in developing molecular tests to determine, without surgery, whether nodules with indeterminate biopsy are cancerous or not. Molecular markers are genes that are expressed in benign or cancerous cells and the presence or absence of these markers in thyroid biopsy specimens can be used to diagnose cancer or to determine that the nodule is benign. The two most common molecular marker tests are the Afirma™ Genomic Sequence Classifier (GSC) and ThyroSeq™. Recently, the GSC has been updated.

In this study, the authors report on the diagnostic accuracy of the GSC in diagnosing cancer in indeterminate thyroid biopsies.

#### THE FULL ARTICLE TITLE

Patel KN et al 2018 Performance of a genomic sequencing classifier for the preoperative diagnosis of cytologically indeterminate thyroid nodules. JAMA Surg. Epub 2018 May 23.

#### SUMMARY OF THE STUDY

In this study, stored thyroid tissue from thyroid biopsies was subject to the GSC test. Tissue was obtained from 210 thyroid nodules from 199 patients in 49 institutions in the United States. All of the patients underwent thyroid surgery, without knowledge of the GSC test prior to surgery. The individuals performing the GSC test had no knowledge of the results of the final pathologic diagnosis and the pathologists examining the surgical thyroid tissue did not know the GSC result.

Of the 210 thyroid nodule specimens included in the study, there was too little molecular material available to perform the GSC test in 19 cases (9%). Thus, the final analysis was planned on the GSC test results in 191 indeterminate cytology thyroid nodules from 183 patients. Approximately one in four nodules in the study was ultimately found to be cancerous at surgery (46/191, 24%), however one of these was excluded from the final analysis. Overall, 41/45 (91%) cancers were correctly detected by the GSC test and 99/145 (68%) of benign nodules that were correctly identified by the GSC test.

#### WHAT ARE THE IMPLICATIONS OF THIS STUDY?

This study shows that the GSC is very good at identifying cancer in indeterminate thyroid biopsies. Further, the current GSC was found to be more specific and results in fewer false positive results as compared to an earlier version of the test. Thus, based on the assumptions that a positive molecular test is an indication for thyroid surgery and a negative test is an indication not to do surgery, the authors concluded that the updated molecular test would be associated with a reduced rate of thyroidectomies for patients with indeterminate cytology thyroid nodules. More research is needed to determine the impact of GSC test utilization on surgical decision-making and long-term health outcomes of patients.

— Anna M. Sawka, MD, PhD





## THYROID NODULES, continued

### ATA THYROID BROCHURE LINKS

Fine Needle Aspiration Biopsy of Thyroid Nodules: <https://www.thyroid.org/fna-thyroid-nodules/>

Thyroid Nodules: <https://www.thyroid.org/thyroid-nodules/>

Thyroid Surgery: <https://www.thyroid.org/thyroid-surgery/>

### ABBREVIATIONS & DEFINITIONS

**Thyroid nodule:** an abnormal growth of thyroid cells that forms a lump within the thyroid. While most thyroid nodules are non-cancerous (Benign), ~5% are cancerous.

**Thyroid fine needle aspiration biopsy (FNAB):** a simple procedure that is done in the doctor's office to determine if a thyroid nodule is benign (non-cancerous) or cancer. The doctor uses a very thin needle to withdraw cells from the thyroid nodule. Patients usually return home or to work after the biopsy without any ill effects.

**Indeterminate thyroid biopsy:** this happens a few atypical cells are seen but not enough to be abnormal (atypia of unknown significance (AUS) or follicular lesion of unknown significance (FLUS)) or when the diagnosis is a follicular or hurthle cell lesion. Follicular and hurthle cells are normal cells found in the thyroid. Current analysis of thyroid biopsy results cannot differentiate between follicular or hurthle cell cancer from noncancerous adenomas. This occurs in 15–20%

of biopsies and often results in the need for surgery to remove the nodule.

**Genes:** a molecular unit of heredity of a living organism. Living beings depend on genes, as they code for all proteins and RNA chains that have functions in a cell. Genes hold the information to build and maintain an organism's cells and pass genetic traits to offspring.

**Molecular markers:** genes and microRNAs that are expressed in benign or cancerous cells. Molecular markers can be used in thyroid biopsy specimens to either to diagnose cancer or to determine that the nodule is benign. The two most common molecular marker tests are the Afirma™ Gene Expression Classifier and ThyroSeq™

**Thyroidectomy:** surgery to remove the entire thyroid gland. When the entire thyroid is removed it is termed a total thyroidectomy. When less is removed, such as in removal of a lobe, it is termed a partial thyroidectomy.







## THYROID CANCER

### Extent of initial surgery may not significantly change survival in patients with localized medullary thyroid cancer

#### BACKGROUND

Medullary thyroid cancer is a rare type of thyroid cancer that often runs in families. The main treatment of medullary thyroid cancer is surgery. Unlike the more common papillary thyroid cancer, radioactive iodine plays no role in the treatment of medullary thyroid cancer. At minimum, the recommended initial operation for patients with medullary thyroid cancer includes surgery to remove the entire thyroid gland (thyroidectomy) and removal of the lymph nodes in the central neck (central neck dissection). However, many patients continue to have less involved initial surgeries. Current guidelines differ on how best to approach a patient with less than the recommended initial operation. The goal of this study was to evaluate the survival of patients with medullary thyroid cancer with localized cancer based on the extent of the initial operation.

#### THE FULL ARTICLE TITLE

Randle RW et al 2018 Survival in patients with medullary thyroid cancer after less than the recommended initial operation. *J Surg Oncol* 117:1211–1216. Epub 2017 Dec 19. PMID: 29266278.

#### SUMMARY OF THE STUDY

This was a study of patients with medullary thyroid cancer diagnosed between 2004 and 2012 using the Surveillance, Epidemiology, and End Results (SEER) registry. Patients with cancer limited to only the central neck area were included. Patients younger than 18 years of age were not included. Patients with cancer that has spread to the lymph nodes on the side of the neck or that has spread from the initial site to other parts of the body also

were not included. Patients included in this study were compared based on the extent of their first operation as recorded in SEER: less than a total thyroidectomy, total thyroidectomy, and total thyroidectomy with removal of lymph nodes.

A total of 766 patients with medullary thyroid cancer were included. A total of 85 patients (11%) had less than a total thyroidectomy, 212 (28%) had a thyroidectomy alone, and 469 (61%) had a total thyroidectomy with removal of lymph nodes. Despite differences in the extent of the initial surgery, survival was similar among the groups. The 5-year disease specific survival (percentage of people in a group who have not died from their cancer five years after diagnosis) was 98.8% in the less than total thyroidectomy group, 98.1% in the total thyroidectomy group, and 97.3% in the total thyroidectomy with lymph node removal group.

#### WHAT ARE THE IMPLICATIONS OF THIS STUDY?

This study showed that according to the SEER registry, the extent of the initial surgery may not significantly change survival in patients with medullary thyroid cancer limited to the central neck. Total thyroidectomy and surgery of the central neck lymph nodes remains the most appropriate initial surgery. However, this study suggests that patients with medullary thyroid cancer that does not have a genetic component and does not run in families with no residual cancer may not need more surgery after less extensive initial operations.

— Priya Mahajan, MD

#### ATA THYROID BROCHURE LINKS

Medullary Thyroid Cancer: <https://www.thyroid.org/medullary-thyroid-cancer/>  
Thyroid Surgery: <https://www.thyroid.org/thyroid-surgery/>





## THYROID CANCER, continued

### ABBREVIATIONS & DEFINITIONS

**Medullary thyroid cancer:** a relatively rare type of thyroid cancer that often runs in families. Medullary cancer arises from the C-cells in the thyroid.

**Thyroidectomy:** surgery to remove the entire thyroid gland. When the entire thyroid is removed it is termed a total thyroidectomy. When less is removed, such as in removal of a lobe, it is termed a partial thyroidectomy.

**Lymph node:** bean-shaped organ that plays a role in removing what the body considers harmful, such as infections and cancer cells.

**Central neck dissection:** careful removal of all lymphoid tissue in the central compartment of the neck

**Central neck compartment:** the central portion of the neck between the hyoid bone above, and the sternum and collar bones below and laterally limited by the carotid arteries.

**SEER:** Surveillance, Epidemiology and End Results program, a nation-wide anonymous cancer registry generated by the National Cancer Institute that contains information on 26% of the United States population. Website: <http://seer.cancer.gov/>

## Thyroid Awareness Monthly Campaigns

The ATA will be highlighting a distinct thyroid disorder each month and a portion of the sales for Bravelets™ will be donated to the ATA. The month of **October** is **Thyroid Nodule Awareness Month** and a bracelet is available through the **ATA Marketplace** to support thyroid cancer awareness and education related to thyroid disease.





## ATA Alliance for Thyroid Patient Education

### GOAL

The goal of our organizations is to provide accurate and reliable information for patients about the diagnosis, evaluation and treatment of thyroid diseases.

We look forward to future collaborations and continuing to work together toward the improvement of thyroid education and resources for patients.

### WHO WE ARE (in alphabetical order)

#### AMERICAN THYROID ASSOCIATION

[www.thyroid.org](http://www.thyroid.org)

ATA Patient Resources:

<http://www.thyroid.org/thyroid-information/>

Find a Thyroid Specialist: [www.thyroid.org](http://www.thyroid.org)

(Toll-free): 1-800-THYROID

[thyroid@thyroid.org](mailto:thyroid@thyroid.org)

#### BITE ME CANCER

<http://www.bitemecancer.org>

[info@bitemecancer.org](mailto:info@bitemecancer.org)

#### GRAVES' DISEASE AND THYROID FOUNDATION

[www.gdatf.org](http://www.gdatf.org)

(Toll-free): 877-643-3123

[info@ngdf.org](mailto:info@ngdf.org)

#### LIGHT OF LIFE FOUNDATION

[www.checkyourneck.com](http://www.checkyourneck.com)

[info@checkyourneck.com](mailto:info@checkyourneck.com)

#### THYCA: THYROID CANCER SURVIVORS' ASSOCIATION, INC.

[www.thyca.org](http://www.thyca.org)

(Toll-free): 877-588-7904

[thyca@thyca.org](mailto:thyca@thyca.org)

#### THYROID CANCER ALLIANCE

[www.thyroidcanceralliance.org](http://www.thyroidcanceralliance.org)

[www.thyroidcancerpatientinfo.org](http://www.thyroidcancerpatientinfo.org)

Rotterdam, The Netherlands

#### THYROID CANCER CANADA

[www.thyroidcancercanada.org](http://www.thyroidcancercanada.org)

416-487-8267

[info@thyroidcancercanada.org](mailto:info@thyroidcancercanada.org)

#### THYROID FEDERATION INTERNATIONAL

[www.thyroid-fed.org](http://www.thyroid-fed.org)

[tfi@thyroid-fed.org](mailto:tfi@thyroid-fed.org)



ThyCa: Thyroid Cancer Survivors' Association, Inc.  
[www.thyca.org](http://www.thyca.org)

THYROID CANCER ALLIANCE





ThyCa: Thyroid Cancer  
Survivors' Association, Inc.<sup>™</sup>  
[www.thyca.org](http://www.thyca.org)



## Thyroid Disease and You...

Do you have any concerns about your thyroid function? Have you or a family member been diagnosed with thyroid disease or have you noticed a lump in your neck?

The American Thyroid Association and our Alliance Partners  
Invite Thyroid Patients and their Families to join us for the:

## 2018 ATA Alliance for Thyroid Patient Education Health Forum

**Saturday, October 6, 2018**

2:00 pm – 4:00 pm

Marriott Marquis Washington, DC

901 Massachusetts Ave NW – Tulip Room, Mezzanine Level

Washington, DC 20001 | Phone: 844-203-5027

ATA Physician Members and our ATA Alliance Partners are available to meet with thyroid patients and their families during the forum. This program is free and open to the public, please register / confirm your participation here: <https://www.eventbrite.com/e/thyroid-disease-and-you-ata-thyroid-education-public-health-forum-tickets-48658607204>

### Who should attend?

Please come if you have questions, symptoms, or concerns about a thyroid problem. We invite anyone who has had an overactive or underactive thyroid, thyroiditis, a thyroid nodule, thyroid cancer, or a family history of thyroid problems or related disorders, including rheumatoid arthritis, juvenile diabetes, or pernicious anemia. Free educational materials will be available for all.

### Reservations requested. Walk-ins welcome.

E-mail [thyroid@thyroid.org](mailto:thyroid@thyroid.org) with any questions or requests for additional information.




American Thyroid Association | 6066 Leesburg Pike, Suite 550 | Falls Church, VA  
[www.thyroid.org](http://www.thyroid.org) | [thyroid@thyroid.org](mailto:thyroid@thyroid.org)



Get the latest thyroid health information. You'll be among the first to know the latest cutting-edge thyroid research that is important to you and your family.

## **Become a Friend of the ATA!** **Subscribe to *Friends of the ATA e-news***

**By subscribing to *Friends of the ATA Newsletter*, you will receive:**

-  *Friends of the ATA e-news*, providing up-to-date information on thyroid issues, summaries of recently published articles from the medical literature that covers the broad spectrum of thyroid disorders., and invitations to upcoming patient events
-  Updates on the latest patient resources through the ATA website and elsewhere on the world wide web
-  Special e-mail alerts about thyroid topics of special interest to you and your family

We will use your email address to send you *Friends of the ATA e-news* and occasional email updates. We won't share your email address with anyone, and you can unsubscribe at any time.

**[www.thyroid.org](http://www.thyroid.org)**



AMERICAN THYROID ASSOCIATION  
ATA | Founded 1923

Donate  
Now!

## JOIN US

### PLEASE JOIN OUR JOURNEY TO ADVANCED DISCOVERIES AND TREATMENT FOR THYROID DISEASE AND THYROID CANCER

As patients with thyroid disease navigate the challenges to their quality of life and researchers and physicians look for more effective directions, we at the ATA have our own destination—**funding for critical thyroid research, prevention, and treatment.** For 94 years, the ATA has led the way in thyroidology. It's a daily obstacle course to find new drugs, better treatments, advanced surgical methods, and more rapid diagnoses for the 20 million Americans who have some form of thyroid disease.

“The ATA was a valuable resource for our family when my dad was diagnosed with Anaplastic Thyroid Cancer. When you're faced with a detrimental diagnosis where even a few days can make the difference in life or death, understanding your options quickly is critical. The ATA website offers a one-stop shop for patients and caregivers to find specialists, current clinical trials, general thyroid cancer information, and links to other patient support groups and information.”

Mary Catherine Petermann

- Father who was diagnosed with Anaplastic Thyroid Cancer in 2006
- He was treated at Mayo Clinic
- He has clean scans as of October 2016

*The ATA has paved the way with management guidelines for clinicians who diagnose and treat thyroid disease. For physicians treating pregnant women diagnosed with thyroid disease, our recent publication presents 97 evidence-based recommendations making sure that best practices are implemented with the latest, most effective treatment.*



Through your generous support and donations, research takes the lead and hope is on the horizon. **Will you join us** in our campaign to raise **\$1.5 million** for thyroid research, prevention, and treatment? Your compassionate, tax-deductible gift will provide funds for:

- Research grants that pave the way for 1,700 ATA physicians and scientists who have devoted their careers to understanding the biology of and caring for patients affected by thyroid disease.
- Patient education for individuals and families looking for life-changing clinical trials, the best thyroid specialists, and cutting edge treatment and drugs.
- Professional education that offers a wealth of knowledge and leading-edge research for trainees and practitioners.
- A website that is the go-to resource for thyroid information for patients and practitioners alike. In 2016 alone, there were more than 3,700,000 website views of ATA's library of online thyroid information patient brochures.

Donations **of all sizes** will change the future for thyroid patients. You will make a direct impact on patients like Mary Catherine's father as he deals with Anaplastic Thyroid Cancer. You will help scientists like ATA Associate Member Julia Rodiger, Ph.D., a scientist at the National Institutes of Health, as she analyzes thyroid hormones for intestinal stem cell development.



# Thyroid Nodules

## WHAT IS THE THYROID GLAND?

The thyroid gland is a butterfly-shaped endocrine gland that is normally located in the lower front of the neck. The thyroid's job is to make thyroid hormones, which are secreted into the blood and then carried to every tissue in the body. Thyroid hormone helps the body use energy, stay warm and keep the brain, heart, muscles, and other organs working as they should.

## WHAT IS A THYROID NODULE?

The term thyroid nodule refers to an abnormal growth of thyroid cells that forms a lump within the thyroid gland. Although the vast majority of thyroid nodules are benign (noncancerous), a small proportion of thyroid nodules do contain thyroid cancer. In order to diagnose and treat thyroid cancer at the earliest stage, most thyroid nodules need some type of evaluation.

## WHAT ARE THE SYMPTOMS OF A THYROID NODULE?

Most thyroid nodules do not cause symptoms. Often, thyroid nodules are discovered incidentally during a routine physical examination or on imaging tests like CT scans or neck ultrasound done for completely unrelated reasons. Occasionally, patients themselves find thyroid nodules by noticing a lump in their neck while looking in a mirror, buttoning their collar, or fastening a necklace. Abnormal thyroid function tests may occasionally be the reason a thyroid nodule is found. Thyroid nodules may produce excess amounts of thyroid hormone causing hyperthyroidism (see [Hyperthyroidism brochure](#)). However, most thyroid nodules, including those that cancerous, are actually non-functioning, meaning tests like TSH are normal. Rarely, patients with thyroid nodules may complain of pain in the neck, jaw, or ear. If a nodule is large enough to compress the windpipe or esophagus, it may cause difficulty with breathing, swallowing, or cause a "tickle in the throat". Even less commonly, hoarseness can be caused if the nodule invades the nerve that controls the vocal cords but this is usually related to thyroid cancer.

The important points to remember are the following:

- Thyroid nodules generally do not cause symptoms.
- Thyroid tests are most typically normal—even when cancer is present in a nodule.
- The best way to find a thyroid nodule is to make sure your doctor checks your neck!

## WHAT CAUSES THYROID NODULES AND HOW COMMON ARE THEY?

We do not know what causes most thyroid nodules but they are extremely common. By age 60, about one-half of all people have a thyroid nodule that can be found either through examination or with imaging. Fortunately, over 90% of such nodules are benign. [Hashimoto's thyroiditis](#), which is the most common cause of hypothyroidism (see [Hypothyroidism brochure](#)), is associated with an increased risk of thyroid nodules. Iodine deficiency, which is very uncommon in the United States, is also known to cause thyroid nodules.

## HOW IS A THYROID NODULE EVALUATED AND DIAGNOSED?

Once the nodule is discovered, your doctor will try to determine whether the rest of your thyroid is healthy or whether the entire thyroid gland has been affected by a more general condition such as hyperthyroidism or hypothyroidism. Your physician will feel the thyroid to see whether the entire gland is enlarged and whether a single or multiple nodules are present. The initial laboratory tests may include measurement of thyroid hormone (thyroxine, or T4) and thyroid-stimulating hormone (TSH) in your blood to determine whether your thyroid is functioning normally.

Since it's usually not possible to determine whether a thyroid nodule is cancerous by physical examination and blood tests alone, the evaluation of the thyroid nodules often includes specialized tests such as thyroid ultrasonography and fine needle biopsy.



# Thyroid Nodules

## THYROID ULTRASOUND:

Thyroid ultrasound is a key tool for thyroid nodule evaluation. It uses high-frequency sound waves to obtain a picture of the thyroid. This very accurate test can easily determine if a nodule is solid or fluid filled (cystic), and it can determine the precise size of the nodule. Ultrasound can help identify suspicious nodules since some ultrasound characteristics of thyroid nodules are more frequent in thyroid cancer than in noncancerous nodules. Thyroid ultrasound can identify nodules that are too small to feel during a physical examination. Ultrasound can also be used to accurately guide a needle directly into a nodule when your doctor thinks a fine needle biopsy is needed. Once the initial evaluation is completed, thyroid ultrasound can be used to keep an eye on thyroid nodules that do not require surgery to determine if they are growing or shrinking over time. The ultrasound is a painless test which many doctors may be able to perform in their own office.

## THYROID FINE NEEDLE ASPIRATION BIOPSY (FNA OR FNAB):

A fine needle biopsy of a thyroid nodule may sound frightening, but the needle used is very small and a local anesthetic may not even be necessary. This simple procedure is often done in the doctor's office. Sometimes, medications like blood thinners may need to be stopped for a few days before to the procedure. Otherwise, the biopsy does not usually require any other special preparation (no fasting). Patients typically return home or to work after the biopsy without even needing a bandaid! For a fine needle biopsy, your doctor will use a very thin needle to withdraw cells from the thyroid nodule. Ordinarily, several samples will be taken from different parts of the nodule to give your doctor the best chance of finding cancerous cells if they are present. The cells are then examined under a microscope by a pathologist.

The report of a thyroid fine needle biopsy will usually indicate one of the following findings:

1. The nodule is benign (noncancerous).
  - This result is obtained in up to 80% of biopsies. The risk of overlooking a cancer when the biopsy is benign is generally less than 3 in 100 tests or 3%. This is even lower when the biopsy is reviewed by an experienced pathologist at a major medical center. Generally, benign thyroid nodules do not need to be removed unless they are causing symptoms like choking or difficulty swallowing. Follow up ultrasound exams are important. Occasionally, another biopsy may be required in the future, especially if the nodule grows over time.

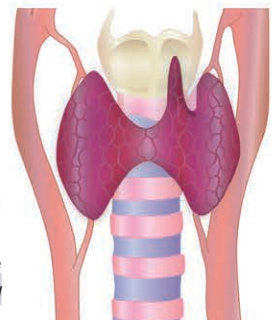
2. The nodule is malignant (cancerous) or suspicious for malignancy .
  - A malignant result is obtained in about 5% of biopsies and is most often due to papillary cancer, which is the most common type of thyroid cancer. A suspicious biopsy has a 50-75% risk of cancer in the nodule. These diagnoses require surgical removal of the thyroid after consultation with your endocrinologist and surgeon.

3. The nodule is indeterminate. This is actually a group of several diagnoses that may occur in up to 20% of cases. An Indeterminate finding means that even though an adequate number of cells was removed during the fine needle biopsy, examination with a microscope cannot reliably classify the result as benign or cancer.
  - The biopsy may be indeterminate because the nodule is described as a Follicular Lesion. These nodules are cancerous 20-30% of the time. However, the diagnosis can only be made by surgery. Since the odds that the nodule is not a cancer are much better here (70-80%), only the side of the thyroid with the nodule is usually removed. If a cancer is found, the remaining thyroid gland usually must be removed as well. If the surgery confirms that no cancer is present, no additional surgery to "complete" the thyroidectomy is necessary.
  - The biopsy may also be indeterminate because the cells from the nodule have features that cannot be placed in one of the other diagnostic categories. This diagnosis is called atypia, or a follicular lesion of undetermined significance. Diagnoses in this category will contain cancer rarely, so repeat evaluation with FNA or surgical biopsy to remove half of the thyroid containing the nodule is usually recommended.
4. The biopsy may also be nondiagnostic or inadequate. This result is obtained in less than 5% of cases when an ultrasound is used to guide the FNA. This result indicates that not enough cells were obtained to make a diagnosis but is a common result if the nodule is a cyst. These nodules may require reevaluation with second fine needle biopsy, or may need to be removed surgically depending on the clinical judgment of your doctor.

## FURTHER INFORMATION

Further details on this and other thyroid-related topics are available in the patient thyroid information section on the American Thyroid Association® website at [www.thyroid.org](http://www.thyroid.org).

For information on thyroid patient support organizations, please visit the [Patient Support Links](http://www.thyroid.org) section on the ATA website at [www.thyroid.org](http://www.thyroid.org)







# Thyroid Nodules

## NUCLEAR THYROID SCANS:

Nuclear scanning of the thyroid was frequently done in the past to evaluate thyroid nodules. However, use of thyroid ultrasound and biopsy have proven so accurate and sensitive, nuclear scanning is no longer considered a first-line method of evaluation. Nuclear scanning still has an important role in the evaluation of rare nodules that cause hyperthyroidism. In this situation, the nuclear thyroid scan may suggest that no further evaluation or biopsy is needed. In most other situations, neck ultrasound and biopsy remain the best and most accurate way to evaluate all types of thyroid nodules.

## MOLECULAR DIAGNOSTICS:

### *Can any other tests assist in evaluation of thyroid nodules?*

Yes, new tests that examine the genes in the DNA of thyroid nodules are currently available and more are being developed. These tests can provide helpful information about whether cancer may be present or absent. These tests are particularly helpful when the specimen evaluated by the pathologist is indeterminate. These specialized tests are done on samples obtained during the normal biopsy process. There are also specialized blood tests that can assist in the evaluation of thyroid nodules. These are currently available only at highly specialized medical centers, however, their availability is increasing rapidly. Ask your doctor if these tests are available and might be helpful for evaluating your thyroid nodule.

## HOW ARE THYROID NODULES TREATED?

All thyroid nodules that are found to contain a thyroid cancer, or that are highly suspicious of containing a cancer, should be removed surgically by an experienced thyroid surgeon. Most thyroid cancers are curable and rarely cause life-threatening problems (see *Thyroid Cancer brochure*). Thyroid nodules that are benign by FNA or too small to biopsy should still be watched closely with ultrasound examination every 6 to 12 months and annual physical examination by your doctor. Surgery may still be recommended even for a nodule that is benign by FNA if it continues to grow, or develops worrisome features on ultrasound over the course of follow up.



## FURTHER INFORMATION

Further details on this and other thyroid-related topics are available in the patient thyroid information section on the American Thyroid Association® website at [www.thyroid.org](http://www.thyroid.org).

For information on thyroid patient support organizations, please visit the *Patient Support Links* section on the ATA website at [www.thyroid.org](http://www.thyroid.org)

