



## THYROID CANCER

# Do patients with low- and intermediate-risk thyroid cancer need continuing post-operative neck surveillance ultrasounds?

### BACKGROUND

Thyroid cancer is the fastest rising cancer in the United States. The vast number of patients do well with an excellent prognosis. This is because of effective treatment with surgery and, when needed, radioactive iodine. Despite this overall excellent prognosis, patients with thyroid cancer face the burden of extended surveillance with neck ultrasounds, which are done to identify abnormal lymph nodes that would indicate cancer recurrence. This is because the lymph nodes in the neck are the most common place for thyroid cancer to recur. Neck ultrasounds are usually performed every 6-12 months to monitor for cancer recurrence but it is unclear when these studies can stop, assuming they are negative. In addition, neck ultrasounds have cost and not a large amount of evidence to support long-term annual tests.

The American Thyroid Association guidelines divide thyroid cancer into low, intermediate and high risk depending on the risk of cancer recurrence after the initial treatment. The vast majority of patients fall into the low and intermediate risk category. In this study, the authors investigated the need for annual ultrasound examinations in low and intermediate risk patients with papillary thyroid cancer.

### THE FULL ARTICLE TITLE

Grani G et al 2019 Thyroid cancer patients with no evidence of disease: the need for repeat neck ultrasound. J Clin Endocrinol Metab Epub 2019 Jun 17. PMID: 31206157.

### SUMMARY OF THE STUDY

The authors examined the medical records of patients at one medical center with low to intermediate risk papillary thyroid cancer treated with surgery (total thyroidectomy) and, if needed, radioactive iodine therapy. The patients were followed over a 7 year period with serial neck ultrasounds and blood tests to measure serum thyroglobulin levels as a cancer marker. The main study outcome was whether there were abnormal lymph nodes seen on a neck ultrasound by 3 years of follow up.

Patients were considered low or intermediate risk of cancer recurrence if their baseline thyroglobulin levels were <1 ng/ml. Out of 226 patients studied meeting this criteria, only 5 had lymph nodes that were considered to not be completely normal on ultrasound 3 years after thyroid cancer treatment. Over the study period, no patients underwent a second operation.

### WHAT ARE THE IMPLICATIONS OF THIS STUDY?

The study authors conclude that patients with low and intermediate risk thyroid cancer who had a total thyroidectomy only need blood tests for thyroglobulin after the first year if their levels are < 1 ng/mL. Therefore, the authors suggest that the yearly neck ultrasound can be avoided in these patients. While these results need to be confirmed with other long term studies, this study is important for patients because it may help them avoid unnecessary tests which helps them save money and minimizes the worry that is common during any thyroid cancer monitoring testing.

— Joshua Klopper, MD

### ATA THYROID BROCHURE LINKS

Thyroid Cancer (Papillary and Follicular): <https://www.thyroid.org/thyroid-cancer/>





**THYROID CANCER, continued**

**ABBREVIATIONS & DEFINITIONS**

**Thyroid Ultrasound:** a common imaging test used to evaluate the structure of the thyroid gland. Ultrasound uses soundwaves to create a picture of the structure of the thyroid gland and accurately identify and characterize nodules within the thyroid. Ultrasound is also frequently used to guide the needle into a nodule during a thyroid nodule biopsy.

**Papillary thyroid cancer:** the most common type of thyroid cancer. There are 4 variants of papillary thyroid cancer: classic, follicular, tall-cell and noninvasive follicular thyroid neoplasm with papillary-like nuclear features (NIFTP).

**Thyroidectomy:** surgery to remove the entire thyroid gland. When the entire thyroid is removed it is termed a total thyroidectomy. When less is removed, such as in removal of a lobe, it is termed a partial thyroidectomy.

**Total thyroidectomy:** surgery to remove the entire thyroid gland.

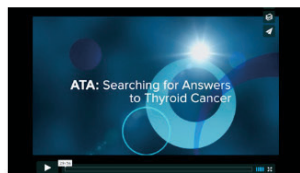
**Thyroglobulin:** a protein made only by thyroid cells, both normal and cancerous. When all normal thyroid tissue is destroyed after radioactive iodine therapy in patients with thyroid cancer, thyroglobulin can be used as a thyroid cancer marker.

**Radioactive iodine (RAI):** this plays a valuable role in diagnosing and treating thyroid problems since it is taken up only by the thyroid gland. I-131 is the destructive form used to destroy thyroid tissue in the treatment of thyroid cancer and with an overactive thyroid. I-123 is the non-destructive form that does not damage the thyroid and is used in scans to take pictures of the thyroid (Thyroid Scan) or to take pictures of the whole body to look for thyroid cancer (Whole Body Scan).

**Lymph node:** bean-shaped organ that plays a role in removing what the body considers harmful, such as infections and cancer cells.

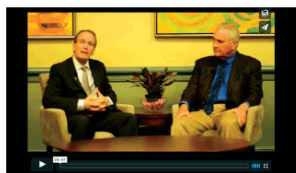**Cancer recurrence:** this occurs when the cancer comes back after an initial treatment that was successful in destroying all detectable cancer at some point.

**Watch how your donations help find answers to thyroid cancer**



The American Thyroid Association (ATA) – Searching for Answers to Thyroid Cancer  
April 17, 2016

♥ 13



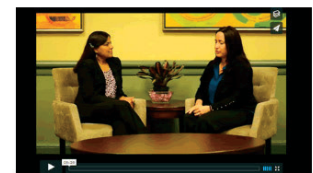Differentiated Thyroid Cancer – Support ATA's ongoing Research  
April 17, 2016

♥ 19



Medullary Thyroid Cancer – Help the ATA Find a Cure  
April 17, 2016

♥ 10



Anaplastic Thyroid Cancer – Support Research for Treatments  
April 17, 2016

♥ 11

[www.thyroid.org/donate/](http://www.thyroid.org/donate/)

