

## External Beam Irradiation and Embolization in the Treatment of Thyroid Carcinoma

Robert F. Gagel  
Division of Internal Medicine  
University of Texas M.D. Anderson Cancer Center  
Houston, TX



THE UNIVERSITY OF TEXAS  
MD ANDERSON  
CANCER CENTER  
*Making Cancer History®*

## No Prospective Studies

- There have been multiple attempts to obtain funding for a prospective trial of XBRT in differentiated and medullary thyroid cancer over the past 15-20 years
  - ◆ All have failed because of concerns regarding inadequate numbers of patients
- Despite this lack of information there is a remarkable consistency of data from retrospective analyses that show XBRT to be effective for local disease control with little effect on overall survival

## External Beam Radiotherapy for Differentiated Thyroid Carcinoma

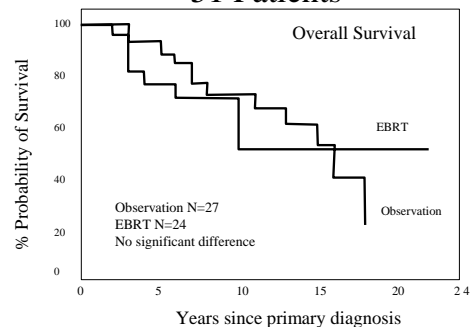
- R41. The use of external beam irradiation should be considered in patients over age 45 with grossly visible extrathyroidal extension at the time of surgery and a high likelihood of microscopic residual disease, and for those patients with gross residual tumor in whom further surgery or radioactive iodine would likely be ineffective.  
Recommendation B

## Medullary Thyroid Carcinoma (MTC)

## ATA Guideline Recommendations for External Beam Radiotherapy for MTC

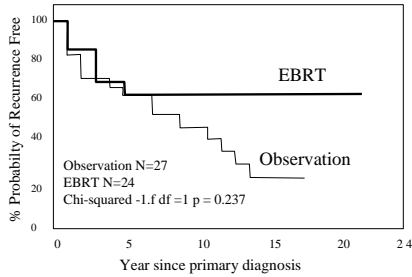
- RECOMMENDATION 92: EBRT should not be used as a substitute for surgery in patients in whom neck tumor foci can be resected without excessive morbidity.  
Recommendation E
- RECOMMENDATION 93: Postoperative EBRT to the neck and mediastinum may be indicated in patients who undergo a gross incomplete resection (R2 resection). Prior to initiating EBRT, physicians should ensure that optimal surgery has been performed as reoperation (other than major ablative procedures) is much more difficult, and may not be safely or technically possible, after EBRT. Recommendation B

## Royal Marsden Experience 51 Patients



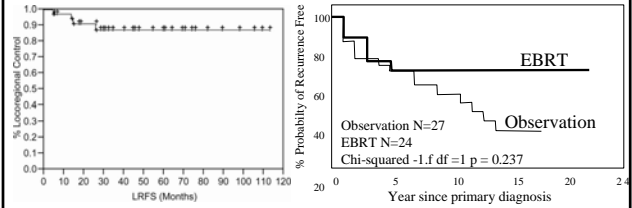
Fersht et al., Thyroid 11: 1161, 2001

### Royal Marsden Experience 51 Patients



Fersht et al., Thyroid 11: 1161, 2001

### Comparison of MDACC and Royal Marsden Experience



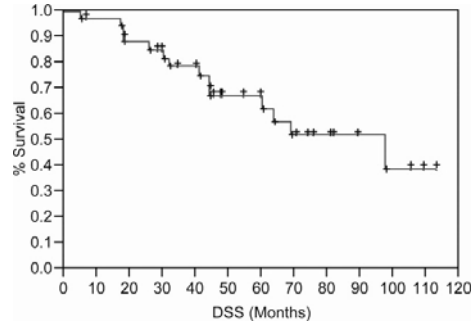
Fersht et al., Thyroid 11: 1161, 2001

### M.D. Anderson Experience with Conformational XBRT

- 34 consecutive patients with stage IVa-c disease Nov 1995-Dec 2004 treated with mean of 60 Gy (36-70)
  - ◆ 10 recurrent disease
  - ◆ 16 with mediastinal involvement
  - ◆ 10 with distant metastasis
  - ◆ 12 with positive surgical margins
- 27 patients received EBRT and 7 intensity modulated radiotherapy (IMRT)
- Median 10 nodes (range 1-55) with median sCT = 556 pg/ml (0-88,000)

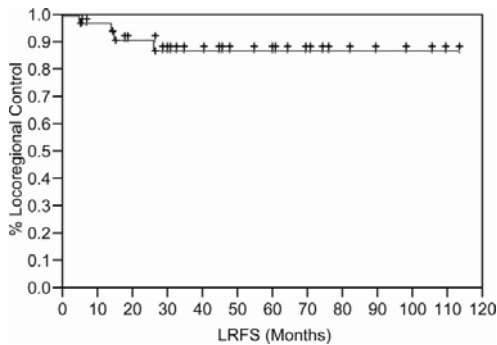
### MDACC Experience

#### Disease-specific Survival (DSS)



Schwartz DL et al., Head & Neck 30: 883, 2008

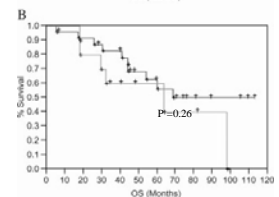
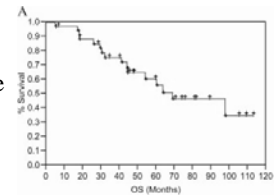
Locoregional relapse-free survival (LRFS) for the study cohort.



Schwartz DL et al., Head & Neck 30: 883, 2008

### MDACC Experience

- Overall survival for the entire study cohort
- Overall survival according to presence/absence of metastatic disease at time of radiation



## Long-term Sequelae of Head and Neck Radiation

- Current radiotherapy techniques that use CT-guided IMRT allow for delivery of adequate dose of radiation, but....
  - ◆ Fibrosis and scarring makes additional surgery more difficult
  - ◆ Neck stiffness, difficulty swallowing, salivary gland secretions decreased
  - ◆ Location of spinal cord immediately behind pharynx can lead to damage
    - Less experienced radiotherapists may deliver inadequate dose because of this concern

## Case Discussion

- 45 YO Male diagnosed with left MTC in 1992
  - ◆ Right completion lobectomy and neck dissection
- (A) RIGHT MODIFIED NECK DISSECTION:
  - ◆ THIRTY OF THIRTY-SEVEN LYMPH NODES CONTAINING METASTATIC MEDULLARY CARCINOMA
- (B) TISSUE BEHIND RIGHT THYROID LOBE:
  - ◆ METASTATIC MEDULLARY CARCINOMA IN SOFT TISSUE
- (C) LEFT LYMPH NODES
  - ◆ ONE OF TWO LYMPH NODES CONTAINING METASTATIC MEDULLARY CARCINOMA
- (D) RIGHT TOTAL THYROIDECTOMY AND PARATRACHEAL LYMPH NODES:
  - ◆ MEDULLARY CARCINOMA OF RIGHT LOBE WITH EXTENSION INTO ISTHMUS AND LEFT LOBE
  - ◆ EIGHT OF EIGHT PARATRACHEAL LYMPH NODES CONTAINING METASTATIC MEDULLARY CARCINOMA
- (E) LEFT ANTERIOR MODIFIED NECK DISSECTION:
  - ◆ FIVE OF EIGHT LYMPH NODES CONTAINING METASTATIC MEDULLARY CARCINOMA

## Realistic Expectations for XBRT in MTC “Living to Fight Another Day”

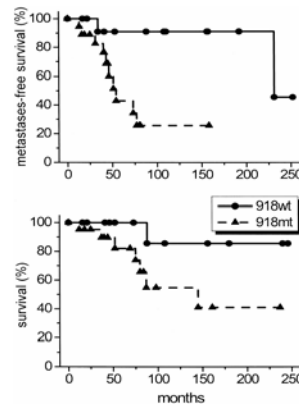
- Multiple reports have documented loco-regional control of disease
- Long-term survival of the patient is determined by metastasis to liver, bone and other distant sites
- XBRT is often effective for preventing further growth of bone and brain metastasis
- Local control of disease progression makes it possible to apply systemic therapies including newer tyrosine kinase therapies

## Case 1

- ◆ Somatic codon 918 RET mutation
- ◆ Received 60 Gy to right neck; 44 Gy to left neck
- ◆ 6 cycles cytotoxic chemotherapy, 2 clinical trials with BMS 214662 and DTIC/Capcitabine/Gleevec without evidence of response
- Enlargement of left hilar node 1996
  - Thoracotomy showed unresectable disease
  - XBRT with 30 Gy
- Hepatic & Pancreatic metastasis 2001-2004
  - Severe episodic abdominal pain related to coeliac plexus involvement by pancreatic metastasis

## Who is a Candidate for XBRT?

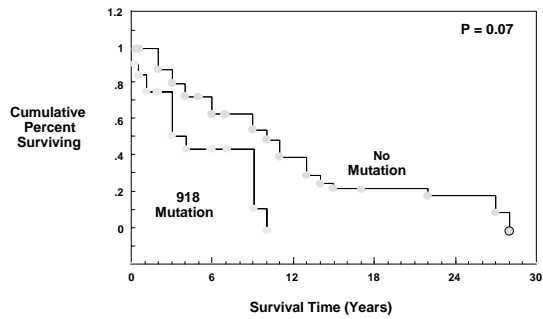
- Patient with several recurrences in the neck or upper mediastinum in whom additional surgery would be difficult
- Microscopic extension of tumor from thyroid gland or lymph node into soft tissue of neck
- Localized unresectable disease
  - ◆ Chest
  - ◆ Bone
  - ◆ Brain



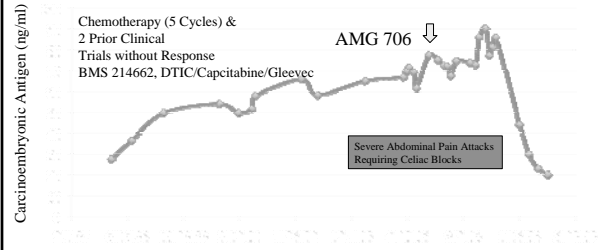
## Somatic 918 Mutations - The German Experience

Schilling T, Int J Cancer 95:62, 2001

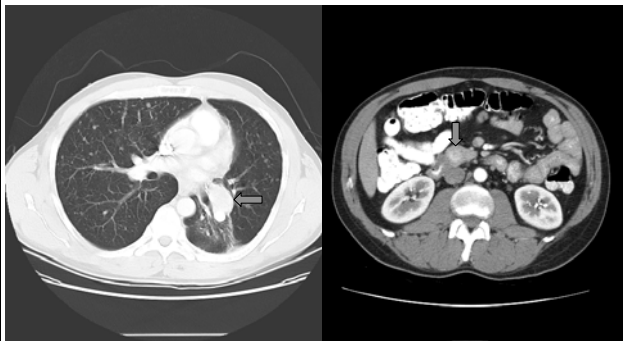
**EFFECT OF A SOMATIC CODON 918 *RET* MUTATION ON SURVIVAL IN SPORADIC MTC**



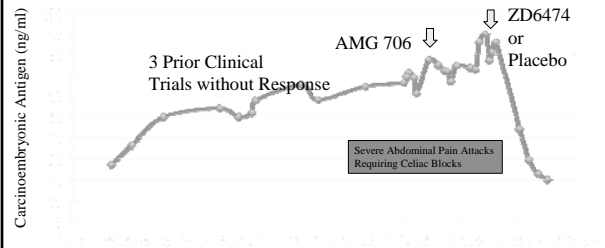
**Case 1**



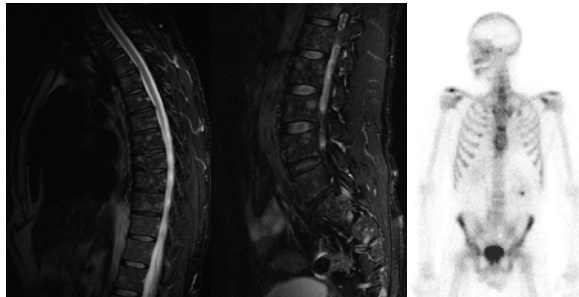
**Case 1**



**Case 1**

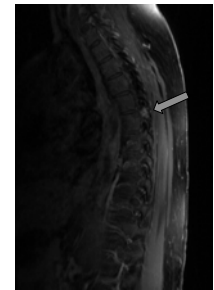

**Localized Bone Metastasis**



**Localized Bone Metastasis**

- Indications for XBRT for bone metastasis
  - ◆ Pain
  - ◆ Risk of pathological fracture
  - ◆ Vertebral metastasis that threaten the spinal cord



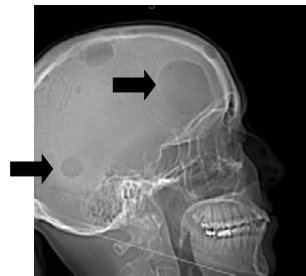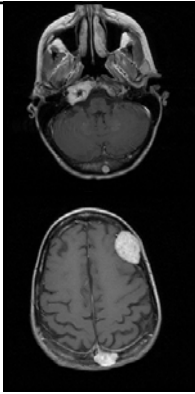
## Brain Metastasis

- Resect if possible
- Consider XBRT
  - ◆ Incomplete resection
  - ◆ Unresectable lesion

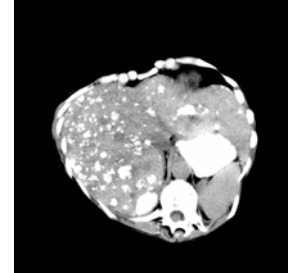
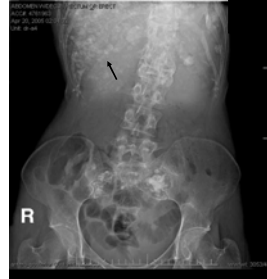## Use of Chemoembolization

- Definition
  - ◆ Infusion of chemotherapeutic agent or gelatin or both into arterial supply of liver or an artery feeding a tumor
    - Obstructs arterial flow to lesion leading to loss of vascularity
    - Liver remains viable because of dual blood supply and regenerative capacity
- Quite useful in carcinoid or VIP producing tumors with hepatic metastasis
- Use in thyroid carcinoma
  - ☞ Reduction of diarrhea/flushing in MTC
  - ☞ Response in slowly growing MTC may be limited because of calcification & amyloid

## Codon 634 DeNovo Mutation and Extensive Metastasis

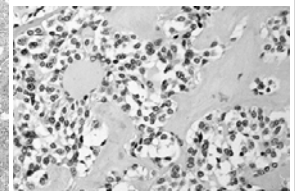
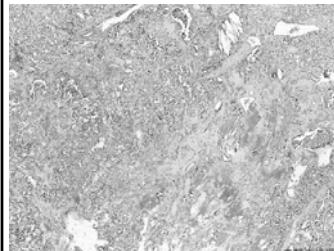


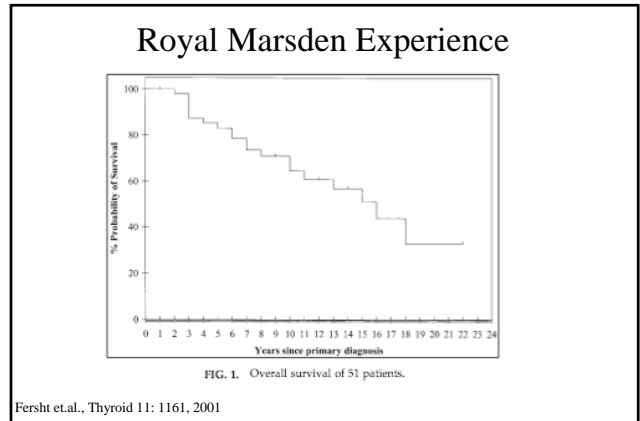
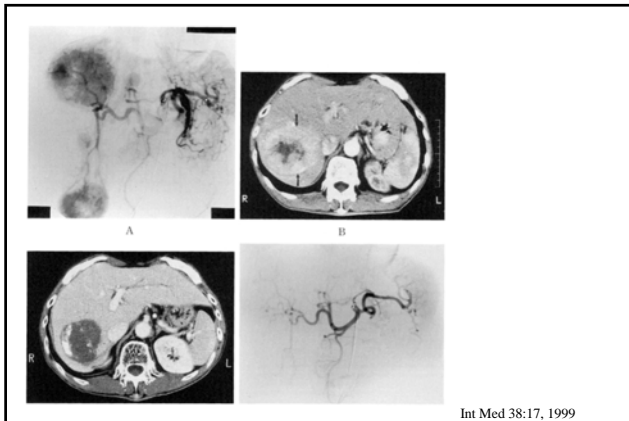
## Patient 3 Calcification of Tumor in Liver



## Chemoembolization

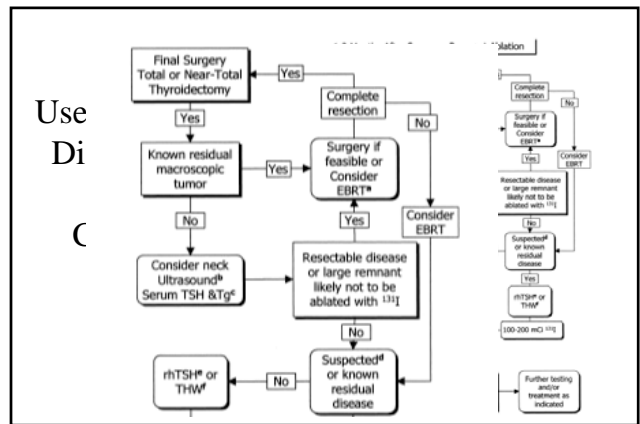
## Amyloid in MTC



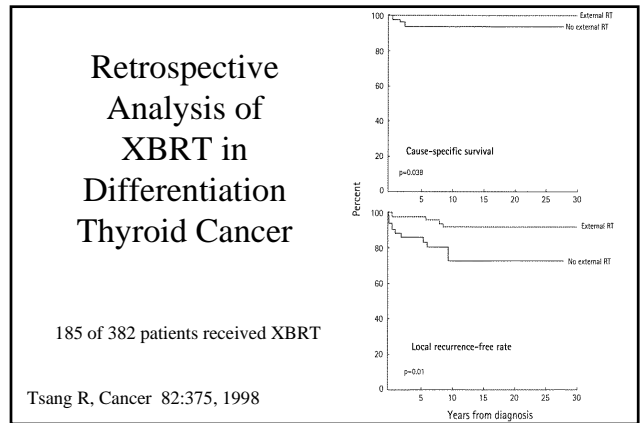


### Other Localized Forms of Therapy

- Radiofrequency ablation
- Cryotherapy
- All local therapies are palliative and do not address the growth of the neoplasm elsewhere



### Differentiated Thyroid Cancer



## Recommendations for XBRT in Differentiated Thyroid Carcinoma

- Consider XBRT for:
  - ◆ Unresectable and RAI negative thyroid cancer in the neck or mediastinum
  - ◆ Microscopic extension of thyroid cancer in soft tissue with no RAI uptake
  - ◆ Multiple surgical procedures for recurrent disease leading to concern about reoperation and RAI negative
  - ◆ Localized cancer in bone or unresectable malignancy in brain (RAI negative)

Questions?